

## A New Method for Volumetric Assessment of Fusion Mass After Posterior Lumbar Interbody Fusion

Ho-Joong Kim, M.D.<sup>1)</sup>, Sun Hyung Lee, M.D.<sup>1)</sup>, Kyoung-Tak Kang, M.S.<sup>2)</sup>,  
Bong-Soon Chang, M.D.<sup>3)</sup>, Choon-Ki Lee, M.D.<sup>3)</sup>, Jin S. Yeom, M.D.<sup>1)</sup>

Spine Center and Department of Orthopaedic Surgery, Seoul National University College of Medicine and Seoul National University Bundang Hospital, Republic of Korea<sup>1)</sup>

Department of Mechanical Engineering, Yonsei University, Seoul, Republic of Korea<sup>2)</sup>

Department of Orthopaedic Surgery, Seoul National University College of Medicine and Seoul National University Hospital, Republic of Korea<sup>3)</sup>

**Purpose:** To assess the volume of fusion mass after posterior lumbar interbody fusion (PLIF) using Hounsfield units methods.

**Methods:** The present study was within the frame work about a prospective observational cohort study to compare the surgical outcomes of a single-level PLIF for LSS between the local bone (LbG) and local bone plus hydroxyapatite groups (LbHa). The fusion material for each case was determined by the amount of available local bone. After the fusion material was chosen, patients were assigned to either the LbG group (n=20) or the LbHa group (n=20). The primary outcome was the assessment of fusion mass volume in each group.

**Results:** We used the new method using Hounsfield units for volumetric assessments of interbody fusion mass. There was no difference in fusion rates or volume of the fusion mass between the 2 groups.

**Conclusions:** Hounsfield unit method, that is the CT-based summation method using a cross-sectional slice, can be applied usefully to other areas of orthopaedics.

**Key Words:** Hounsfield units, Hydroxyapatite, Posterior lumbar interbody fusion, Bone transplantation

### Introduction

Recent studies have demonstrated that local bone graft is as beneficial as autologous iliac bone graft for posterior interbody fusion (PLIF) at the single level.<sup>1-3)</sup> However, depending on the extent of decompression, the amount of local bone available may not be sufficient for interbody fusion, especially for a single-level fusion surgery. In such cases, porous hydroxyapatite has been reported to be a useful bone graft extender.<sup>4-9)</sup> There is another rationale for using an additional bone graft extender in that insufficient size of fusion mass may limit effective load transmission.<sup>10,11)</sup>

However, there has been no prospective comparative study evaluating the efficacy of hydroxyapatite as a bone graft extender compared to using only local bone graft.

Furthermore, the association between the size of the fusion mass and clinical outcomes has yet to be clarified. For the clarification of above concerns, the exact assessment of fusion mass volume is the prerequisite. Therefore, we aimed to introduce new method of volumetric assessment of fusion volume in the patient with PLIF using local bone graft alone (LbG group) and local bone graft plus porous hydroxyapatite bone chip (LbHa group) for the treatment of LSS.

**Corresponding author:** Jin S. Yeom, M.D.

Spine Center and Department of Orthopaedic Surgery, Seoul National University College of Medicine and Seoul National University Bundang Hospital, 166 Gumiro, Bundang-gu, Sungnam, 463-707, Republic of Korea

**TEL:** 82-31-787-7195, **FAX:** 82-31-787-4056

**E-mail:** highcervical@gmail.com

\*There is no conflict of interest in this study.

## Methods

### Study design and patients

The present study was within the frame work about a prospective observational cohort study to compare the surgical outcomes of a single-level PLIF for LSS between the local bone (LbG) and local bone plus hydroxyapatite groups (LbHa). The study design was approved by the hospital's institutional review board. All participants provided written informed consent before enrolling in the study. The inclusion criteria included an age of 40 to 80 years, an LSS diagnosis, and scheduled PLIF surgery at the single level. LSS was diagnosed when one or more of the following symptoms were present: leg pain, numbness, or motor deficits in the lower extremities and buttocks,<sup>12,13)</sup> along with a confirmed stenotic lesion in the lumbar spine by magnetic resonance imaging (MRI). Furthermore, patients were excluded if they had a history of peripheral vascular disease, any concurrent serious medical condition causing disability, or general health status that included sepsis or cancer.

### Allocation of participants

#### LbG group

A single midline incision of approximately 8 cm in length was made, followed by exposure of the spine to the facet joints and the lateral tips of the transverse processes to allow for clear identification of the bony landmarks. First, a pedicle screw was inserted using the Weinstein method. Following decompression procedures, including laminectomy and facetectomy, discectomy and endplate preparation were performed. Local lamina and facet bone byproducts were morselized with the removal of soft tissue, sclerotic bone, and cartilage. For osteoinductive agent, 2.5 g of demineralized bone matrix (DBM) (Bone-Fuse®, Bioalpha Inc., Seongnam, Korea) was mixed with the prepared local bone. After the mixture with prepared local bone and DBM was packed in the disc space, 1 or 2 cages filled with local bone graft were inserted. Finally, the rods were assembled with pedicle screws and fastened.

#### LbHa group

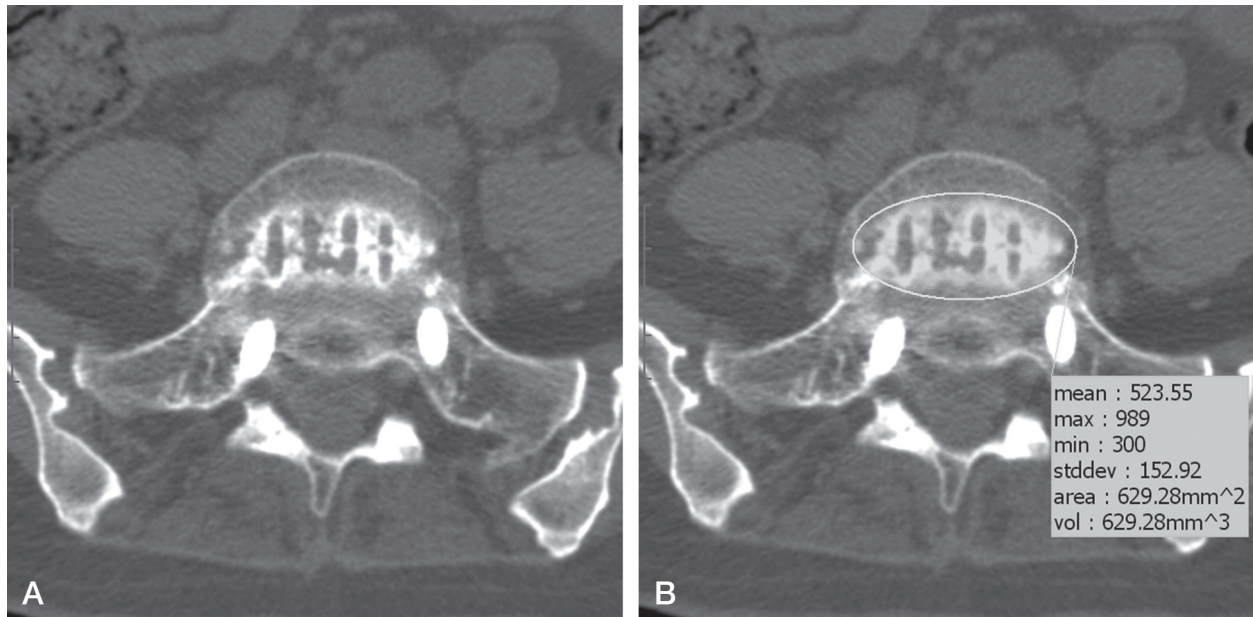
The same PLIF procedure was performed in patients

in the LbHA group. However, after discectomy and endplate preparation, the morselized local bone, 2.5 g of DMB (Bone-Fuse®, Bioalpha Inc., Seongnam, Korea) and 0.25 g of porous hydroxapatite (Bongros-HA®, Bioalpha Inc., Seongnam, Korea) were packed in the disc space. Thereafter, 1 or 2 cages filled with local bone graft were inserted.

### Radiological outcome assessment

The radiological assessments were performed by 3 independent observers who were blinded to the purpose of the study, the patients' clinical information, and the outcomes recorded by the other observers. The fusion status was assessed using computed tomography (CT) 1 year after surgery. Complete bony fusion was defined when there was continuous contact of the trabecular bone between the upper and lower endplates of the fusion segments, mature bony trabecular bridging of the interbody space, cortication at the peripheral edges of the fusion masses, and an absence of identifiable radiographic clefts.<sup>14-16)</sup> If there was a difference in fusion status among the 3 observers, the opinion which 2 observers agreed with was considered as the final status.

The volume of the interbody fusion mass was assessed with CT images 1 year after surgery using the Rapidia 3D 2.8 software (Infinit, Inc., Seoul, Korea). From the lower endplate, a slice was chosen from the region of interest (ROI) where the interbody fusion mass was first observed in the disc space, and each consecutive axial slice was viewed until no fusion mass was visible. Using the Rapidia 3D 2.8 manual segmentation tool, an outline of the fusion mass was traced on the selected axial slices. Tracing the outline of the fusion mass seen in these axial slices ensured that structures from the upper endplate to the lower endplate were included (Fig. 1). With the aid of the Rapidia 3D 2.8 volume tool, the size of the fusion mass was calculated for each axial slice. The summation of the size of the fusion masses in all axial slices was considered as the volume of the interbody fusion mass. To reduce the possibility of including soft tissue rather than bone volume, a thresholding technique was used. The software was directed to include only those pixels that had values between 300 and 1,000 Hounsfield units for the LbG group and 300 and 1,200 Hounsfield units for the



**Fig. 1. (A)** Axial computed tomography images of the interbody fusion mass in the local bone graft (LbG) alone group. **(B)** The observer manually drew an eclipse circle, which was considered to include the fusion mass depicted in Figure 2a. Inside the eclipse circle, the software highlighted the fusion mass area with Hounsfield units between 300 and 1,000. The highlighted cross-sectional area of fusion mass was automatically calculated and the summation of the cross-sectional area was considered as the volume of the fusion mass.

LbHa group. Based on previous studies, 3 independent observers considered that a threshold between 300 and 1,000 was optimal for measuring the volume of the fused mass, including the cancellous portion, in the LbG group.<sup>17,18)</sup> For the LbHa group, further adjustment was necessary because of the porous hydroxyapatite bone chip area; hence, the upper range of Hounsfield units was increased to 1,200 (Fig. 1).

For interobserver and intraobserver reliability tests, an interclass correlation (ICC) coefficient (kappa) (3.1) was calculated with a target ICC value of 0.8 and a 95% confidence interval of 0.2, with the setting of a single measurement and absolute agreement.<sup>19)</sup> A minimum of 36 cases was required to form the sample size. Following interobserver reliability testing, one of the independent observers repeated the radiographic measurements to assess intraobserver reliability, with an interval of 4 weeks between the 2 measurement sessions.

## Statistical analysis

Continuous and categorical variables were compared between the 2 groups using an independent t-test and chi-square test, respectively. All statistical analyses were per-

formed with SPSS 20.0.0 statistics package (IBM Corporation, Armonk, NY), with an alpha level of significance set at 0.05.

## Results

Between December 2012 and October 2013, 47 patients were assessed for study eligibility. Forty participants met the inclusion criteria. According to the chosen fusion method, patients were assigned to either the LbHa group (n=20) or the LbG group (n=20). Figure 1 shows the number of patients involved in the present study, from eligibility assessment through the 12-month follow-up assessment. At the 12-month assessment after surgery, complete data were available for 19 and 17 patients in the LbHa and LbG groups, respectively. The baseline characteristics and preoperative symptom severities of the patients were similar between the 2 groups (Table 1). All patients had a single-level lumbar stenotic lesion.

The fusion rate was not different between the groups (p=0.935). One non-union case was noted in each group. Thus, the fusion rate was 94.7% and 94.1% for the LbHa and LbG groups, respectively (p=0.935). The measure of fusion

**Table 1.** Descriptive statistics of the subjects in the study. Values are mean ± SD

	LbHa (20)	LbG (20)	P value
Age (years)	62.9 ± 6.6	70.00 ± 5.62	0.409
Female, n (%)	15 (75.0)	14 (70.0)	0.723
BMI (kg/cm <sup>2</sup> )	23.53±2.59	24.45 ± 1.38	0.169
VAS for back pain	7.1 ± 2.2	6.9 ± 2.5	0.835
VAS for leg pain	7.5 ± 2.3	6.8 ± 2.9	0.431
ODI	49.1 ± 19.5	40.7 ± 14.9	0.134
Symptom duration (months)	12.3 ± 5.6	13.5 ± 8.3	0.322
Walking distance at a single trial (min)	10.4 ± 10.8	12.8 ± 13.9	0.673
SF-36 PCS	39.7 ± 10.1	37.4 ± 8.6	0.597
SF-36 MCS	30.8 ± 6.8	32.1 ± 7.8	0.822
Operated level (n)	L3 – L4 : 2 L4 – L5: 13 L5 – S1: 5	L3 – L4 : 1 L4 – L5: 16 L5 – S1: 3	

BMI: body mass index, SD: standard deviation, VAS: Visual Analog PainScale, ODI: Oswestry Disability Index, SF-36; Short Form-36, PCS: Physical Component Summary, MCS: Mental Component Summary.

**Table 2.** Comparison of fusion rates (%) and volume of fusion mass (mm<sup>3</sup>)

	LbHa	LbG	P value
Fusion rate (%)	94.7	94.1	0.935
Volume of fusion mass (mm <sup>3</sup> )	5220.7 ± 1438.4	4626.9 ± 1841.5	0.723

LbG group; fusion using local bone graft alone, LbHa group; fusion using local bone graft plus porous hydroxyapatite bone chip.

mass volume using CT showed satisfactory interobserver and intraobserver reliabilities in that ICC (95% CI) was 0.873 (0.650–0.947) and 0.915 (0.842–0.952), respectively. The mean volume of the interbody fusion mass was 5220.7 ± 1438.4 mm<sup>3</sup> and 4626.9 ± 1841.5 mm<sup>3</sup> in the LbHa and LbG groups, respectively, and no difference in the fusion mass was observed between the 2 groups (p=0.333) (Table 2).

## Discussion

We aimed to investigate the usefulness of a new method for volumetric assessment of interbody fusion mass. To our knowledge, the method to quantify the amount of fusion mass in the present study was firstly implemented for volumetric assessment of fusion mass, even though the reference value of Hounsfield units in the fusion mass was reported.<sup>17)</sup> A previous study demonstrated the successful measurement

of the jaw bone volume using the method implemented in this study.<sup>20)</sup> Another study has shown that the computer-based methods used to estimate the volume of irregularly shaped masses are reliable and recommend their use for film readers with limited radiologic experience.<sup>21)</sup> However, the fusion mass volume does not always represent a large area of contact surface between the vertebral body and fusion mass in terms of stress distribution and load sharing, as the height of the fusion mass also contributes to the overall volume. Nevertheless, because of the irregular shape of the fusion mass, we considered that the volume of fusion mass would be a better measurement than the cross-sectional area of fusion mass at the endplate.

In conclusion, the CT-based summation method using a cross-sectional slice can be applied usefully to other areas of orthopaedics. Furthermore, the present study showed that the LbHa group had similar fusion rates, compared to the

LbG group.

## REFERENCES

- Ito Z, Matsuyama Y, Sakai Y, et al. Bone union rate with autologous iliac bone versus local bone graft in posterior lumbar interbody fusion. *Spine (Phila Pa 1976)*. 2010;35:E1101-5.
- Ito Z, Imagama S, Kanemura T, et al. Bone union rate with autologous iliac bone versus local bone graft in posterior lumbar interbody fusion (PLIF): a multicenter study. *Eur Spine J*. 2013;22:1158-63.
- Ohtori S, Suzuki M, Koshi T, et al. Single-level instrumented posterolateral fusion of the lumbar spine with a local bone graft versus an iliac crest bone graft: a prospective, randomized study with a 2-year follow-up. *Eur Spine J*. 2011;20:635-9.
- Kaiser MG, Groff MW, Watters WC, 3rd, et al. Guideline update for the performance of fusion procedures for degenerative disease of the lumbar spine. Part 16: bone graft extenders and substitutes as an adjunct for lumbar fusion. *J Neurosurg Spine*. 2014;21:106-32.
- Brodano GB, Giavaresi G, Lolli F, et al. Hydroxyapatite-Based Biomaterials vs. Autologous Bone Graft in Spinal Fusion: An in Vivo Animal Study. *Spine (Phila Pa 1976)*. 2014.
- Kurd M, Cohick S, Park A, Ahmadinia K, Lee J, An H. Fusion in degenerative spondylolisthesis: comparison of osteoconductive and osteoinductive bone graft substitutes. *Eur Spine J*. 2014.
- Neen D, Noyes D, Shaw M, Gwilym S, Fairlie N, Birch N. Healos and bone marrow aspirate used for lumbar spine fusion: a case controlled study comparing healos with autograft. *Spine (Philadelphia, Pa. 1976)*. 2006;31:E636-40.
- Ylinen P, Kinnunen J, Laasonen EM, et al. Lumbar spine interbody fusion with reinforced hydroxyapatite implants. *Archives of orthopaedic and trauma surgery*. 1991;110:250-6.
- Kim H, Lee CK, Yeom JS, Lee JH, Lee KH, Chang BS. The efficacy of porous hydroxyapatite bone chip as an extender of local bone graft in posterior lumbar interbody fusion. *Eur Spine J*. 2012;21:1324-30.
- Kumar N, Judith MR, Kumar A, Mishra V, Robert MC. Analysis of stress distribution in lumbar interbody fusion. *Spine (Phila Pa 1976)*. 2005;30:1731-5.
- Lee JH, Jeon DW, Lee SJ, Chang BS, Lee CK. Fusion rates and subsidence of morselized local bone grafted in titanium cages in posterior lumbar interbody fusion using quantitative three-dimensional computed tomography scans. *Spine (Phila Pa 1976)*. 2010;35:1460-5.
- Katz JN, Harris MB. Clinical practice. Lumbar spinal stenosis. *N Engl J Med*. 2008;358:818-25.
- Watters WC, 3rd, Baisden J, Gilbert TJ, et al. Degenerative lumbar spinal stenosis: an evidence-based clinical guideline for the diagnosis and treatment of degenerative lumbar spinal stenosis. *Spine J*. 2008;8:305-10.
- McAfee PC, Regan JJ, Geis WP, Fedder IL. Minimally invasive anterior retroperitoneal approach to the lumbar spine. Emphasis on the lateral BAK. *Spine (Phila Pa 1976)*. 1998;23:1476-84.
- Lee JH, Lee JH, Park JW, Lee HS. Fusion rates of a morselized local bone graft in polyetheretherketone cages in posterior lumbar interbody fusion by quantitative analysis using consecutive three-dimensional computed tomography scans. *Spine J*. 2011;11:647-53.
- Fogel GR, Toohey JS, Neidre A, Brantigan JW. Fusion assessment of posterior lumbar interbody fusion using radiolucent cages: X-ray films and helical computed tomography scans compared with surgical exploration of fusion. *Spine J*. 2008;8:570-7.
- Spruit M, Meijers H, Obradov M, Anderson PG. CT density measurement of bone graft within an intervertebral lumbar cage: increase of hounsfield units as an indicator for increasing bone mineral content. *J Spinal Disord Tech*. 2004;17:232-5.
- Robertson DD, Sharma GB, Gilbertson LG, Kang JD. Bone densitometry within titanium lumbar interbody fusion cages: a computed tomography feasibility study. *Spine (Phila Pa 1976)*. 2009;34:2792-6.
- Bonett DG. Sample size requirements for estimating intraclass correlations with desired precision. *Stat Med*. 2002;21:1331-5.
- Bianchi J, Fiorellini JP, Howell TH, et al. Measuring the efficacy of rhBMP-2 to regenerate bone: a radiographic study using a commercially available software pro-



gram. Int J Periodontics Restorative Dent. 2004;24:579-87.

21. Tiitola M, Kivisaari L, Tervahartiala P, et al. Estimation

or quantification of tumour volume? CT study on irregular phantoms. Acta Radiol. 2001;42:101-5.

## 후방 요추체간 유합술 이후 유합골의 용적 측정에 대한 새로운 방법

김호중<sup>1)</sup>, 이선형<sup>1)</sup>, 강경택<sup>2)</sup>, 장봉순<sup>3)</sup>, 이춘기<sup>3)</sup>, 염진섭<sup>1)</sup>

분당서울대학교병원 정형외과학교실<sup>1)</sup>, 연세대학교 기계공학교실<sup>2)</sup>, 서울대학교병원 정형외과학교실<sup>3)</sup>

**목적:** 후방 척추체간 유합술을 한 분절에서 시행하는데 있어, 골이식 시에 국소골만을 이용한 경우와 수산화인회석을 골이식 확장제로 사용한 경우의 결과를 비교한 전향적 연구는 아직 발간된 바 없다. 또한, 유합골의 용적과 임상적 결과와의 관계도 뚜렷하게 밝혀진 바가 없다. 이를 위해서는 유합골의 정확한 용적을 구하는 것이 필수적으로, 본 연구에서는 하운스필드 유닛(Hounsfield Units) 방법을 이용하여 후방 요추체간 유합술 이후 생긴 유합골극의 용적을 구해보고자 한다.

**대상 및 방법:** 본 연구는 전향적 코호트 관찰연구로서, 척추관협착증 환자에서 한 분절에 대해 후방 요추체간 유합술을 시행할 때 국소골을 사용한 집단(LbG)과 국소골에 수산화인회석을 추가하여 사용한 집단(LbHa)의 수술후 결과를 비교하여보고자 한다. 수술 중 얻어진 국소골의 양에 따라 어떠한 방법으로 유합술을 진행할 것인가를 결정하였고, 이에 따라 환자는 LbG 집단(n=20) 혹은 LbHa 집단(n=20)으로 배정되었다. 각각의 집단에서 측정된 유합골의 용적을 일차 유효성 평가 변수로 하였다.

**결과:** 유합골의 용적을 하운스필드 유닛(Hounsfield Units)를 이용한 새로운 방법으로 측정하였다. 양 집단에서 유합률은 각각 94.7% (LbG) 및 94.1% (LbHa)로 통계적으로 유의한 차이는 없었다(p=0.935). 양 집단에서 유합골 용적은 각각  $5220.7 \pm 1438.4 \text{ mm}^3$  (LbG) 및  $4626.9 \pm 1841.5 \text{ mm}^3$  (LbHa)로 통계적으로 유의한 차이는 없었다(p=0.333).

**결론:** 컴퓨터 단층촬영을 기반으로 단면적을 이용한 용적 측정 방법인 하운스필드 유닛(Hounsfield Unit) 방법은 다른 정형외과 영역에도 유용하게 응용될 수 있으리라 생각된다.

**색인 단어:** 하운스필드 유닛, 수산화인회석, 후방 요추체간 유합술, 골이식