

Effect of Regenerating Liver Cytosol on Liver Regeneration in Rats with Liver Cirrhosis

쥐의 간경변증에서 간재생에 대한 재생 간세포 추출물의 효과

Kuhn Uk Lee* and Joseph G. Fortner**

* Department of Surgery, College of Surgery, Seoul National University

** Gastric and Mixed Tumor Service, Department of Surgery, Memorial Sloan-Kettering Cancer Center

INTRODUCTION

The nature and origin of the regeneration promoting substances remain in dispute. Portal blood factors have a specific effect on hepatic regeneration following partial hepatectomy. Starzl et al(1973, 1979) proposed the multifactorial hypothesis. The pancreatic control was the most important, but the other nonhepatic splachnic organs did also some role in regeneration after partial hepatectomy in their experiment using the evisceration procedures.

An additional question is whether they initiate regeneration or merely permit the process to proceed. While portal blood factors clearly influence hepatic regeneration, they may not initiate this process but merely play a permissive role(Bucher et al., 1978; Price, 1976). The actual genesis may start in the liver itself(Levi et al., 1971). The interaction of factors that originate within the liver can contribute, regulate, or even initiate the actual development of liver regeneration after liver cell necrosis or partial hepatectomy. Labreque and Pesch(1975) demonstrated regenerative stimulator in the supernatant of an extract of rat liver mash. The regenerative stimulator was present not only in

the liver mash of very young rat, but in the active regenerating remnant liver after partial hepatectomy in adult rat(LaBreque, 1979; Makowka, 1983).

Liver cytosol fractions not only stimulate the rate of liver regeneration after partial hepatectomy in rats and dogs or after portacaval shunts in dogs(Starzl et al., 1979), but also after toxin-induced hepatic necrosis(Makowka et al., 1981) and in a model of acute ethanol-induced inhibition of hepatic regeneration(Makowka, 1983).

In acute hepatic failure this regenerating liver cytosol(RLC) dose the deliverate enhancement or stimulation of regeneration in surviving or uninjured liver cells and the promotion of repair in the acutely damaged liver which has not respond with suitable or spontaneous regeneration.

Starzl(1979) demonstrated that RLC promoted liver regeneration after partial hepatectomy in dogs and when it was injected into the portal vein in the presence of Eck fistula.

Makowka et al(1981, 1983) demonstrated that the intraperitoneal administration of a heat-stable non-insulin or glucagon-containing liver cytosol preparation could significantly improve survival in a rat model of D-galactosamine-induced suppression of post-hepatectomy regeneration.

† 1984년 7월 9일 접수

But in cases of liver cirrhosis liver regeneration has been known to be meager in the remnant liver after its partial removal.

We studied the effect of RLC in the rat with liver cirrhosis to see if RLC could stimulate the rate of liver regeneration after partial resection of the liver with chronic hepatic necrosis.

MATERIALS AND METHODS

I. Animals

The inbred male Wistar strain rats weighing about 150 gm were purchased from Charles River Laboratories.

All animals were housed in a central animal facility of room temperature with $74 \pm 2^\circ \text{F}$ ($23 \pm 1.1^\circ \text{C}$) on a 12-hour light/dark cycle.

The rats were divided into liver cirrhosis and normal group. Above each group contained experimental (Regenerating Liver Cytosol) and control (Saline) group respectively.

II. Liver Cirrhosis

Crystalline phenobarbitone which "sensitize" the liver to the toxic action of CCl_4 , was made up in tap water to a concentration of 35mg/dl and given for 14 days.

Thereafter 0.1 ml of carbon tetrachloride (CCl_4) mixed with same amount of olive oil was given by intragastric cannula twice a week for 12 weeks. Liver biopsy was performed to see the pathologic changes of the liver, and checked the body weight periodically.

III. Preparation of regenerating liver cytosol (R.L.C.)

Healthy inbred adult male Wistar strain rats weighing between 400 and 450 gm were used. Anesthesia was induced by ether and maintained with intra-peritoneal injection of 0.1 cc Ketalar (Ketamine HCL 20 mg/ml).

The 68 per cent hepatectomy was performed by removal of the median and left lateral lobes of the liver between 9 and 11 AM.

The remnant regenerating liver was removed 24 hours later. The cytosol extracts from the regenerating livers were prepared by the method of LaBreque and Pesch (1975).

A 35% (w/v) homogenate in 0.9 per cent NaCl solution was prepared from the excised livers with a motor driven Wheaton overhead stirrer (homogenizer).

The homogenate was centrifuged at 145,000 gm and 4°C for 2 hours in a Servall RC2 ultracentrifuge.

The upper most white lipid layer was carefully sucked out, then clear reddish-yellow supernatant were used.

IV. Preparation of recipient rats

The 34 per cent or 68 per cent hepatectomy were performed between 11 AM and 2 PM on ether anesthesia with intraperitoneal injection of 0.1 cc Ketalar.

The 34 per cent hepatectomy was underwent by removal of the left lateral lobe of the liver and the 68 per cent hepatectomy was performed by the same as the those of the donor rats.

The experimental group was injected by 5ml aliquots (150 mg protein) of the fraction 4-6 hours following hepatectomy intraperitoneally, whereas the control group was received 5 ml 0.9 per cent saline solution by same route at the same time with the experimental group after hepatectomy.

Hepatectomies were performed from 11 AM to 2 PM to minimize fluctuations due to diurnal rhythm.

V. Determination of incorporation of ^3H -thymidine into hepatic D.N.A.

Ninety minutes before sacrificing 100 μCi ^3H -thymidine (^3H -TdR, 6.7 Ci/mmol, New England Nuclear, Boston, M.A.) was injected into the intra-peritoneal cavity of the rats.

Exactly 24 hour after hepatectomy all rats were sacrificed, then the remained livers were removed for extraction of DNA under ether

anesthesia.

DNA was extracted by the method of Weinbren and Woodward(1964), except that trichloroacetic acid(TCA) was used instead of perchloric acid.

Samples of 600 ± 20 mg were homogenized in 10 ml 0.9 per cent saline in a Wheaton homogenizer and the suspension was divided approximately equally. After adding 0.4 ml 5 N-TCA the suspension was immediately stirred and centrifuged. The precipitate was extracted successively at room temperature with 5ml alcohol-ether(3:1, v/v), alcohol-chlorform (3:1, v/v) and ether, and the residue was digested with 5ml 0.3 N-KOH at 37°C overnight in a stoppered tube. The digest was cooled in the deep freeze for 30 min, acidified with 0.4 ml 5 N-TCA, stirred and spun. After washing twice with 5 ml water, the residue was extracted with 6.5 ml 0.5 N-TCA at 70°C for 20 minutes, cooled in the deep freeze for 40 minutes and then centrifuged.

A portion(1 ml) of the supernatant was diluted to 5 ml with distilled water and the extinction at $260\text{ m}\mu$ was measured against a similar dilution of 0.5 N-TCA.

A further 2 ml of supernatant was mixed with

15 ml of Aquasol(Universal L.S.C. Cocktail, New England Nuclear, Boston, M.A.) and the radioactivity was measured in a liquid scintillation spectrometer(Packard Troca).

Radioactive counts per minute per its optical density in the $260\text{ m}\mu$ ultraviolet length(CPM/O.D.) were compared with each other group.

RESULTS

I. Liver Cirrhosis

During the period of ingestion of CCl_4 , 22 of the 80 rats(27.5%) were died. Almost all rats were died of hepatic failure, with symptoms and signs of pale, diarrhea, weight loss, petechiae, retroperitoneal hemorrhage and jaundice.

About at 8 weeks of ingestion of ccl_4 , jaundice was definitely noticed in all rats. The grossly fine nodular lesions on the livers was seen at 8 weeks by open liver biopsy, with diffuse fibrosis and structually abnormal nodules observed microscopically.

At 12 weeks severe liver cirrhosis with ascites was found in one-third of survival rats. Collateral circulation around liver was also found in severe cases.

Table 1. The comparative results in 34 and 68% hepatectomy of the rats with the normal and cirrhotic liver.

liver pathology	animal number	body weight	magnitude of hepatectomy	intraperitoneal injection of	excised liver weight	remnant liver weight	spleen weight	CPM/OD	p value
normal	3	461.7	34%	saline	4.36	11.82	0.90	368.5 ± 67.6	<0.01
normal	4	450.0	34%	cytosol	4.17	11.05	0.78	669.7 ± 150.6	
normal	3	490.0	68%	saline	10.05	6.95	0.87	4631.2 ± 1055.7	>0.05
normal	5	461.0	68%	cytosol	9.94	6.76	0.71	4697.4 ± 572.7	
L.C.	4	410.8	34%	saline	5.36	10.71	1.43	302.0 ± 154.2	<0.01
L.C.	5	388.0	34%	cytosol	6.15	9.45	1.39	677.9 ± 149.5	
L.C.	4	431.3	68%	saline	13.07	8.38	1.50	933.9 ± 158.1	>0.05
L.C.	6	461.7	68%	cytosol	15.24	8.08	1.51	1582.2 ± 1204.8	

L.C.; liver cirrhosis C.P.M.; count per minute O.D.; optical density

The comparative results of intraperitoneal injection of regenerating liver cytosol(RLC) and saline by radioactive counts per minute per its optical density in the $260\text{ m}\mu$ ultraviolet length(C.P.M./O.D.) after 34 and 68% hepatectomy in the rats with the normal and cirrhotic liver.

Liverweight was heavier in the non-ascites group compared to the ascites group in the liver cirrhosis (Table 2).

The average spleen weight of the group with liver cirrhosis was 1.46 gm, which meant the increase of 85 per cent for those of normal group (0.79 gm).

Spleen weight was lighter in the non-ascites group than the ascites group in the liver cirrhosis (Table 2).

Both findings were statistically significant. ($P < 0.01$)

But the relationships between liver or spleen weight and radioactive count were not evaluated because of small size of animal number in this experiment.

II. 34 per cent Hepatectomy

In the normal rat group intraperitoneal injection of RLC increased the incorporation of ^3H -TdR into the hepatic DNA by 2-fold.

In the rats with liver cirrhosis intraperitoneal injection of RLC also augmented the hepatic incorporation of ^3H -TdR by same magnitude.

Above augmentations in both groups were statistically highly significant. ($P < 0.01$), (Figure 1, Table 1)

The differences of the incorporations between the normal liver group and the group of liver cirrhosis both in cases of using saline or RLC were not statistically significant.

III. 68 per cent Hepatectomy

In the 68 per cent hepatectomy of the normal rats the hepatic incorporation of ^3H -TdR was augmented more than 12 times those of 34 per cent hepatectomy of the normal rats.

Table 2. The relationship between liver, spleen weight and ascites

Ascites	Liver weight*	Spleen weight**
+	17.15 \pm 2.68	1.64 \pm 0.40
-	21.24 \pm 4.70	1.33 \pm 0.34

*, **; $0.01 < p < 0.05$

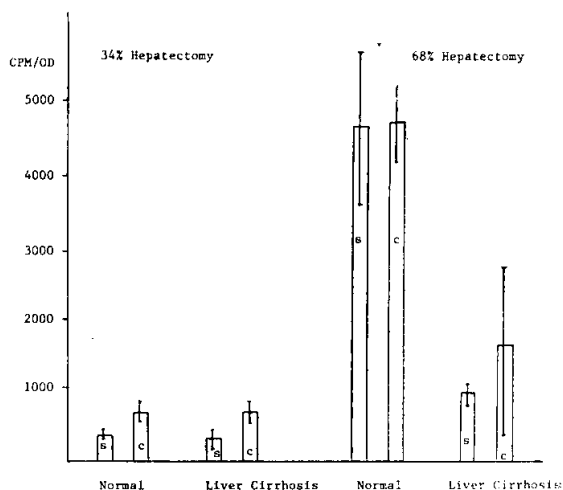


Fig. 1. The effects of regenerating liver cytosol(RLC) in the control normal liver group and the experimental cirrhotic liver group in cases of 34% and 68% hepatectomy respectively. RLC could induce augmentation of ^3H -TdR uptake into DNA of the liver cell in the 34% hepatectomy of both normal and cirrhotic liver groups ($p < 0.01$), RLC could not increase ^3H -TdR uptake in the 68% hepatectomy of normal liver group, but it could increase ^3H -TdR uptake in the 68% hepatectomy of liver cirrhosis group ($p > 0.05$).

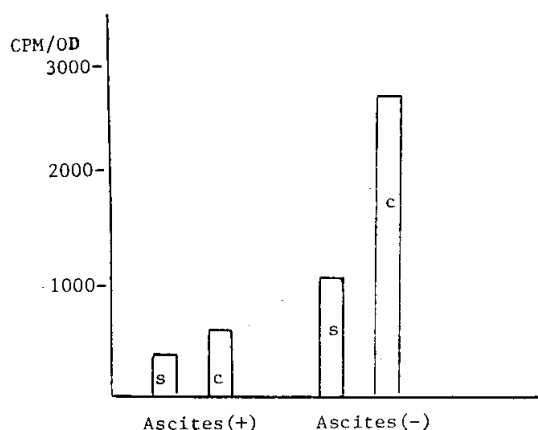


Fig. 2. The effects of regenerating liver cytosol(RLC) in the liver cirrhosis with or without ascites in the rats. RLC could not sufficiently augment ^3H -TdR uptake into DNA of the liver cell in the liver cirrhosis with ascites, but in the absence of ascites RLC could augment liver regeneration at the same rate with that of the normal liver group ($p < 0.01$).

But the incorporation of ^3H -TdR was not augmented by RLC in the 68 per cent hepatectomy of the normal rats compared to that of saline control group.

In the rats with liver cirrhosis the incorporation of ^3H -TdR was decreased to the level of 20% of those of the normal rats in the 68 per cent hepatectomy.

Intraperitoneal injection of RLC augmented that value by almost 1.7-fold, but which was still only one-third value of the normal rats. (Figure 1, Table 2)

This increase in ^3H -TdR uptake was not statistically significant because the cytosol group contained severe liver cirrhosis and the augmentation of the incorporation by RLC was meager in this severe liver cirrhosis with ascites and the contracted liver compared to mild to moderate cirrhosis. (Figure 2)

^3H -TdR uptake into DNA were increased in both ascites and non-ascites groups, but RLC did not induce liver regeneration sufficiently enough to overcome the stress of the 68 per cent hepatectomy.

RLC could induce liver regeneration in the non-ascites group up to more than half level of ^3H -TdR uptake of the normal rats.

DISCUSSION

Anthony et al(1978) defined liver cirrhosis as a diffuse process characterized by fibrosis and the conversion of normal liver architecture into structurally abnormal nodules.

Cameron and Karunaratne(1936) reported that the minimum toxic dose for the rats liver by the subcutaneous rout lies between 0.005 and 0.0025 cc, i.e. 0.033~0.016 per kg. body weight.

After single toxic dose of carbon tetrachloride removal of damaged and necrotized liver cells proceeds by the fourteenth day.

A certain, repeated dose at short intervals over a long period is necessary for the production of liver cirrhosis in the rat by means of carbon tetrachloride.

Moon(1934) considered that the cirrhosis produced by carbon tetrachloride satisfied rigid criteria for Laennec's cirrhosis.

There are two stages in the development of carbon tetrachloride cirrhosis;

1) a pre-cirrhotic reversible stage, with histological features indistinguishable from actual cirrhosis and 2) a cirrhotic stage with a finely or coarsely granular liver.

Mann, Fishback, Gay and Green(1931) found in dogs with carbon tetrachloride cirrhosis that there was little restoration of the cirrhotic liver after its partial removal as compared with that of normal liver and restoration did not occur when the cirrhosis was well developed.

Cameron and Karunaratne(1936) reported some observation of partially hepatectomized rats, that in the "precirrhotic stage" the removal of one-half to two-thirds of the liver was followed rapidly by complete regeneration, but very little restoration occurred after partial hepatectomy as the cirrhotic stage became more complete.

Chatamra and Proctor(1981) reported that severe cirrhosis of the liver(defined as a shrunken finely nodular liver with micronodular histology, ascites greater than 30ml, plasma albumin less than 2.2g/dl, splenomegaly 2~3 times normal, and testicular atrophy approximately half normal weight) was increased from 25% to 56% by giving the initial "calibrating" doses of CCl_4 at the peak of the phenobarbitone induced enlargement of the liver. In our experiment one-third had severe liver cirrhosis by using the phenobarbitone and CCl_4 . They were found to have ascites and shrunken finely nodular liver with micronodular histology, and splenomegaly. Two-third had mild to moderate liver cirrhosis, with the enlarged liver and splenomegaly, but

without ascites. They did not recover to normal liver architecture and gain body weight for several months after the carbon tetrachloride had been discontinued.

In the one-third hepatectomy of normal liver group intraperitoneal injection of RLC produced a two fold increase in incorporation of tritiated thymidine (^3H -TdR) into hepatic DNA.

This finding was the same as those of other reports (Cameron et al., 1936; LaBreque, 1979; Makowka, 1983).

In the one-third hepatectomy of liver cirrhosis group RLC augmented the DNA uptake of ^3H -TdR by almost same degree as those of the normal liver group. In the two-third hepatectomy RLC revealed much different effect on liver regeneration for those of one-third hepatectomy. In the normal liver group stimuli to liver regeneration was appeared to be maximum, so DNA uptake of ^3H -TdR was not increased even by using RLC. But in the liver cirrhosis group RLC exerted some augmentation effect on liver regeneration according to the amount of functional reservoir of the sound liver cell. When the liver cirrhosis was mild or moderate, augmentation of incorporation of ^3H -TdR into DNA of the liver cell was marked. But in the cases of severe cirrhosis increase of ^3H -TdR uptake into DNA in the liver cell was not noticed.

So we could speculate that the stimuli to the liver regeneration after partial hepatectomy may probably be the amount of loss of the normal liver cell, and also the normal liver cell itself might be the origin of factor(s) involved in or controlling its regeneration.

There may be upper limit in regeneration capacity of the liver cell. Beyond this limit liver regeneration after partial resection of the liver could not occur even by using RLC.

RLC was effective in augmentation of liver regeneration after partial hepatectomy in the rat

with mild and moderate cirrhosis.

But in the severe liver cirrhosis RLC was not effective in augmentation of the liver regeneration after partial hepatectomy.

The ascites and the contracture of the liver were much correlated with the amount of liver regeneration after partial hepatectomy in the rat with liver cirrhosis. In the process of making the liver cirrhosis, some of them compensated to the toxic injury of CCl_4 by liver regeneration, and their liver became enlarged. But in the rats with the contracted liver compensatory liver regeneration did not occur during the toxic injury of CCl_4 , so their reservoir of the liver were thought to be inadequate to survive the partial resection of their liver.

RLC may be helpful in the resection of the cirrhotic liver with marginal reservoir of liver function when severe contracture of the liver and ascites are not found.

SUMMARY

Liver cirrhosis was tried to develop in the 80 inbred male Wistar strain rats by pretreatment of phenobarbitone and intermittent oral ingestion of carbon tetrachloride, among which one-third of the survived (72.5%) had severe liver cirrhosis with the ascites and the contracted liver, and two-third had irreversible mild to moderate liver cirrhosis.

Regenerating liver cytosol (RLC) was prepared in the remnant liver 24 hours after two-third hepatectomy in the normal rats by ultracentrifugation (145,000 gm).

Five ml of RLC (150 mg protein) was intraperitoneally injected 4~6 hours after partial hepatectomy in both liver cirrhosis and normal liver groups. Whereas control group was intraperitoneally injected by same amount of saline.

In one-third hepatectomy two-fold augmentations of ^3H -TdR uptake into DNA of the liver

cell were noticed in both normal and liver cirrhosis groups by using RLC compared with saline injection in both normal liver and liver cirrhosis groups.

In two-third hepatectomy ^3H -TdR augmentation was not noticed in normal liver group even by using RLC for saline injection in normal liver group. There may be upper limit in regeneration capacity of the liver cell. But in liver cirrhosis group the augmentation of ^3H -TdR was variable, i.e. RLC exerted some augmentation effect on liver regeneration according to the amount of functional reservoir of the sound liver cell.

The ascites and the contracture of the liver were much correlated with the amount of liver regeneration after partial hepatectomy in the rat with liver cirrhosis.

RLC may be helpful in the resection of the cirrhotic liver with marginal reservoir of liver function when severe contracture of the liver and ascites are not found.

＝국문초록＝

쥐의 간경변증에서 간재생에 대한 재생 간세포 추출물의 효과

서울대학교 醫科大學 外科學敎室 및 Memorial Sloan-Kettering Cancer Center
李健旭 · Joseph G. Fortner

80마리의 숫컷 wistar 근교계 쥐에서 phenobarbitone의 전 처치와 CCl_4 의 간헐적 경구투여로 간경변증을 일으키려고 시도하여, 그중 생존된 쥐(72.5%)의 1/3에서 복수 및 수축된 간을 동반한 중증의 간경변증과 2/3에서 불가역성의 정도 및 증증도의 간경변증이 발생되었다. 재생간세포 추출물은 정상쥐에서 2/3 간절제술 24시간후 잔존된 간에서 초원심분리(145,000gm)로 추출되었다.

재생간세포 추출물 5ml(150mg 단백질)을 간경변증과 정상간군 모두에 부분 간절제술 4~6시간후에 복강 내에 주사하였다.

반면 대조군은 동량의 생리식염수를 복강내 주입하였다. 1/3 간절제술에서 정상간 및 간경변증군 모두에서 재생 간세포 추출물 사용으로 생리식염수 주사한 정상군 및 간경변증군에 비하여 간세포내 DNA에 ^3H -TdR 흡착이 2배의 증강이 관찰 되었다.

2/3 간절제술에서 정상간군에서는 재생 간세포 추출물을 사용하더라도 생리식염수를 주사한 정상간군에 비해 ^3H -TdR 증강이 관찰되지 않았다. 이것으로 봐서 간세포의 재생능력에는 한계가 있을 것으로 추정된다.

그러나 간경변증군에서는 ^3H -TdR의 증강은 정상 간세포의 기능보유량에 따라 재생간세포 추출물의 간재생에 대한 증강효과가 차이가 있었다. 복수 및 수축된 간은 간경변증이 동반된 쥐에서 부분 간절제술후 간재생량에 많은 관계가 있었다.

재생 간세포 추출물은 간의 심한 수축과 복수가 발견되지 않을 때 간기능의 보유가 제한된 경변증이 있는 간을 절제함에 있어서 도움이 되리라 사료된다.

REFERENCES

- Anthony P.P., Ishak K.G., Nayak N.C., Poulsen H.E., Scheuer P.J. and Sobin L.H.: *The Morphology of Cirrhosis. J. of Clinical Pathology* 31:395-414, 1978.
- Bucher N.L.R., Weir G.C.: *Insulin, Glucagon, Liver Regeneration, and DNA Synthesis. Metabolism* 25: 1423, 1978.
- Cameron G.R. and Karunaratne W.A.K.: *Carbon Tetrachloride Cirrhosis in relation to Liver Regeneration. The J. of Pathology and Bacteriology, Vol. XVII No. 1, 1936.*
- Chatamra K. and Proctor E.: *Phenobarbitone-Induced Enlargement of the Liver in the Rat; Its Relationship to Carbon Tetrachloride-Induced Cirrhosis. Br. J. Exp. Path.* 62:283, 1981.
- LaBrique D.R., Pesch L.A.: *Preparation and Partial Characterization of Hepatic Regenerative Stimulator Substance from Rat Liver. J. Physiol.* 248:273-284, 1975.
- LaBrique D.R.: *The Role of Hepatotrophic Factors in Liver Regeneration. The Yale Journal of Biology and Medicine* 52:49-60, 1979.
- Levi J.U., Zeppa R.: *Source of the Humoral Factor that initiates Hepatic Regeneration. Ann. Surg.* 174:

- 364-370, 1971.
- Makowka L., Rotstein L.F., Falk R.E.: *Allogenic and Xenogeneic Hepatocyte Transplantation. Transplant Proc.* 30:429-431, 1981.
- Makowka L., Falk R.E., Falk J.A., Teodorczyk-Injeyan J., Venturi D., Rotstein L.E., Falk W., Langer B., Blendis L.M. and Phillips M.J.: *The Effect of Liver Cytosol on Hepatic Regeneration and Tumor Growth. Cancer* 51:2181-2190, 1983.
- McLean E.K., McVean A.E.M. and Sutton P.M.: *Instant Cirrhosis, An Improved Method for Producing Cirrhosis of the Liver in Rats by Simultaneous Administration of Carborn Tetrachloride and Phenobarbitone. Br. J. Exp. Path.* 50:502, 1969.
- Mann F.C., Fishback F.C., Gay J.G. and Green G. F.: *Experimental Pathology of the Liver. Arch. Path.* 12:787-793, 1931.
- Moon V.H.: *Experimental Cirrhosis in relation to Human Cirrhosis. Arch. Path.* 18:381-424, 1934.
- Price Jr. J.B.: *Insulin and Glucagon as Modifiers of DNA Synthesis in the Regenerating Rat Liver. Metabolism* 25:1427, 1976.
- Starzl T.E., Francavilla A., Halgrimson C.G., Francavilla F.R., Porer K.A., Brown T.H. and Putnam C.W.: *The Origin, Hormonal Nature and Action of Portal Venous Hepatotrophic Substances. Surg. Gynecol. & Obst.* 137:179, 1973.
- Starzl T.E., Terblanche J.: *Hepatotrophic Substances. Progress in Liver Diseases, Vol. VI* 135-151, 1979.
- Starzl T.E., Jones A.F., Terblanche J., Usui S., Porter K.A. and Mazzoni G.: *Growth Stimulating Factor in Regenerating Canine Liver. Lancet* 1:127-130, 1979.
- Terblanche J., Porter K.A., Starzl T.E., Moore J., Patzelt L. and Hayashida N.: *Stimulation of Hepatic Regeneration after Partial Hepatectomy by Infusion of a Cytosol Extract from Regenerating Dog Liver. Surg. Gynecol. & Obst.* 151:538-544, 1980.
- Weinbren K., Woodward E.: *Delayed Incorporation of ³²P from Orthophosphate into Deoxyribonucleic Acid of Rat Liver after Subtotal Hepatectomy. Br. J. Exp. Path.* 45:442-449 1964.

LEGENDS FOR FIGURES

- Fig. 1.** 8th week, H-E stain $\times 100$: Grossly jaundice and micronodular liver surface and found at the first time. Diffuse fatty change and increase of fibrocollagenous tissue in central to portal and portal to portal areas are noticed. Inflammatory cell (mainly lymphocytes) in periportal areas, and neutrophils and eosinophils in parenchyme are infiltrated.
- Fig. 2.** 10th week, H-E stain $\times 100$: Fibrosis in portal to portal and portal to central areas is increased with accentuated marginal nodularity. Many hyperchromatic hepatocytes are scattered in parenchyme.
- Fig. 3.** 13rd week, H-E stain $\times 100$: Small nodules in the center are surrounded by widened portal spaces and fine septa between one central vein and another central vein are found.
- Fig. 4.** 13rd week, Reticulin stain $\times 40$: Mild liver cirrhosis. Slight reticulin condensations are found in portal to portal spaces with disarray and decrease of reticulin fiber around the central veins. (One-third hepatectomy, Regenerating liver cytosol injection group, CPM/OD:1022.8)
- Fig. 5.** 16th week, Reticulin stain $\times 40$: Moderate liver cirrhosis. More condensations of reticulin fiber are developed in portal spaces with increase of fine reticulin fiber in central to portal and central to central areas (Two-third hepatectomy, Regenerating liver cytosol injection group, CPM/OD:2231.5)
- Fig. 6.** 15th week, Reticulin stain $\times 40$: Moderate liver cirrhosis. More condensations of reticulin fiber are noticed in portal spaces with large and small nodule formation. (Two-third hepatectomy, Saline injection group, CPM/OD:843.5)
- Fig. 7.** 16th week, Reticulin stain $\times 40$: Severe liver cirrhosis. Marked condensations of reticulin fiber are occurred in portal spaces with round parenchymal margins. (Two-third hepatectomy, Regenerating liver cytosol injection group, CPM/OD:490.3)
- Fig. 8.** 15th week, Masson's Trichrome stain $\times 40$: Severe liver cirrhosis. Variable sized newly formed nodules are surrounded by fibrous band. (Two-third hepatectomy, Regenerating liver cytosol injection group, CPM/OD:545.1)

* Above noted weeks are the day of biopsy or experiment. All of the rats were fed by 14 days of crystalline-phenobarbitone and 12 weeks of carbon tetrachloride.

